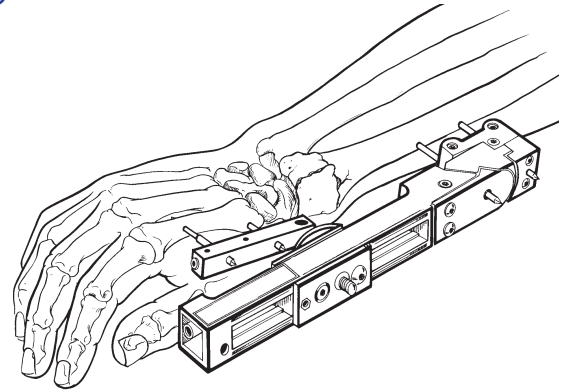


# Agee WristJack<sup>®</sup>

Multiplanar Ligamentotaxis<sup>™</sup>

## Fracture Reduction System

**Fracture reduction and external fixation  
for treatment of distal radius fractures**



**Surgeon's Manual**



**Restoring Length to Radius**

## **QUICK REFERENCE GUIDE**

**Rotational Alignment**

**Dorsal/Palmar Translation**

**Radial/Ulnar Alignment**

**Wrist Position**



## WristJack Fracture Reduction System

---

***Designed, tested and produced in an  
environment that unites patient care and  
research to define innovative products.***

*—Hand Biomechanics Lab, Inc.*

# **WristJack Fracture Reduction System**

*Item No. CFD-147*

---

Designed by: John M. Agee, M.D.

Engineered by: John M. Agee, M.D. and Francis C. King

United States Patents #4548199, 4611586 and 4922896

Foreign patents applied for.

Surgeon's Manual, Part No. 306000R, 01/03

© 1990 - 2003 Hand Biomechanics Lab, Inc.

All Rights Reserved.

Multiplanar Ligamentotaxis is a trademark of Hand Biomechanics Lab, Inc.

WristJack, intertwined arrows and hand/arc logo are all registered trademarks of Hand Biomechanics Lab, Inc.

Hand Biomechanics Lab, Inc.

77 Scripps Drive, Suite 104

Sacramento, CA 95825

[www.handbiolab.com](http://www.handbiolab.com)

(800) 522-5778 (916) 923-5073 (916) 920-2215 Fax

## TABLE OF CONTENTS

---

Introduction to the WristJack	1
Instrumentation and Sterilization	2
Indications For Use	4
Surgical Anatomy and Incisions	6
Metacarpal Pin Insertion	8
Radial Shaft Pin Insertion	12
Installing the Metacarpal Bar	20
Installing the WristJack on the Pins	22
Selective Fracture Reduction: Length	24
Selective Fracture Reduction: Rotation	26
Selective Fracture Reduction: Dorsal/Palmar Translation	28
Selective Fracture Reduction: Radial/Ulnar Alignment	30
Wrist Position for Optimal Hand Function	32
Final Check and Analysis	34
Clinical Course and Fixator Removal	36
Reference	38
Important Medical Information	41

## A COMMENT ABOUT MEDICAL DEVICES

---

Patient compliance is important to ensure successful outcomes when using medical devices such as the WristJack Fracture Reduction System. Before using any device, it is helpful to discuss the rationale and use with the patient. This discussion should include the surgical procedure, patient responsibilities, length of treatment and potential complications.



# INTRODUCTION

---

## Design

The biomechanical design of the WristJack complements the anatomy of a fracture of the distal radius. Its gear mechanisms permit independent adjustment of:

- Length
- Dorsal/palmar fragment translation
- Radial/ulnar fragment alignment
- Rotational alignment at the fracture site
- Wrist position in the flexion-extension plane

The WristJack is molded of a high performance engineering resin that permits radiographic translucency. The surgical approach and instrumentation have been developed to avoid injury to important anatomical structures.

## ***Multiplanar Ligamentotaxis™***

Traditionally, external skeletal fixators have used ligamentotaxis to restore skeletal length through the application of traction forces parallel to the forearm. Over a

decade of laboratory and clinical research has demonstrated that ligamentotaxis in dorsal/palmar and radial/ulnar planes is capable of tilting the distal radial articular surface back toward normal if satisfactory soft tissue hinges remain intact.

The WristJack is designed with gear-driven adjustments that take advantage of functionally intact soft tissue hinges to achieve ligamentotaxis in multiple planes, or *Multiplanar Ligamentotaxis*. (Refer to page 38 in the Reference section for further information.)

## **Selective Fracture Reduction**

Adjustments can be made in any one of three planes without affecting fracture alignment in the remaining two planes. Wrist extension can be selected to minimize finger stiffness and the risk of carpal tunnel syndrome without compromising fracture reduction. In addition to giving the surgeon control over fracture reduction during surgery, the WristJack allows “fine tuning” of the fracture alignment in the clinic, gently and without pain.

## INSTRUMENTATION AND STERILIZATION

---

The WristJack Fracture Reduction System is provided **STERILE** and for **SINGLE USE** only.

The system includes pins and the following instrumentation necessary for application.

- Long Thread Pins (3)
- Short Thread Pins (2)
- Drill Guide: Metacarpal
- Drill Guide: Radius
- Pin Placement Guide: Radius
- Hex Screwdriver
- Hex “L” Wrench
- Pin Caps (4)

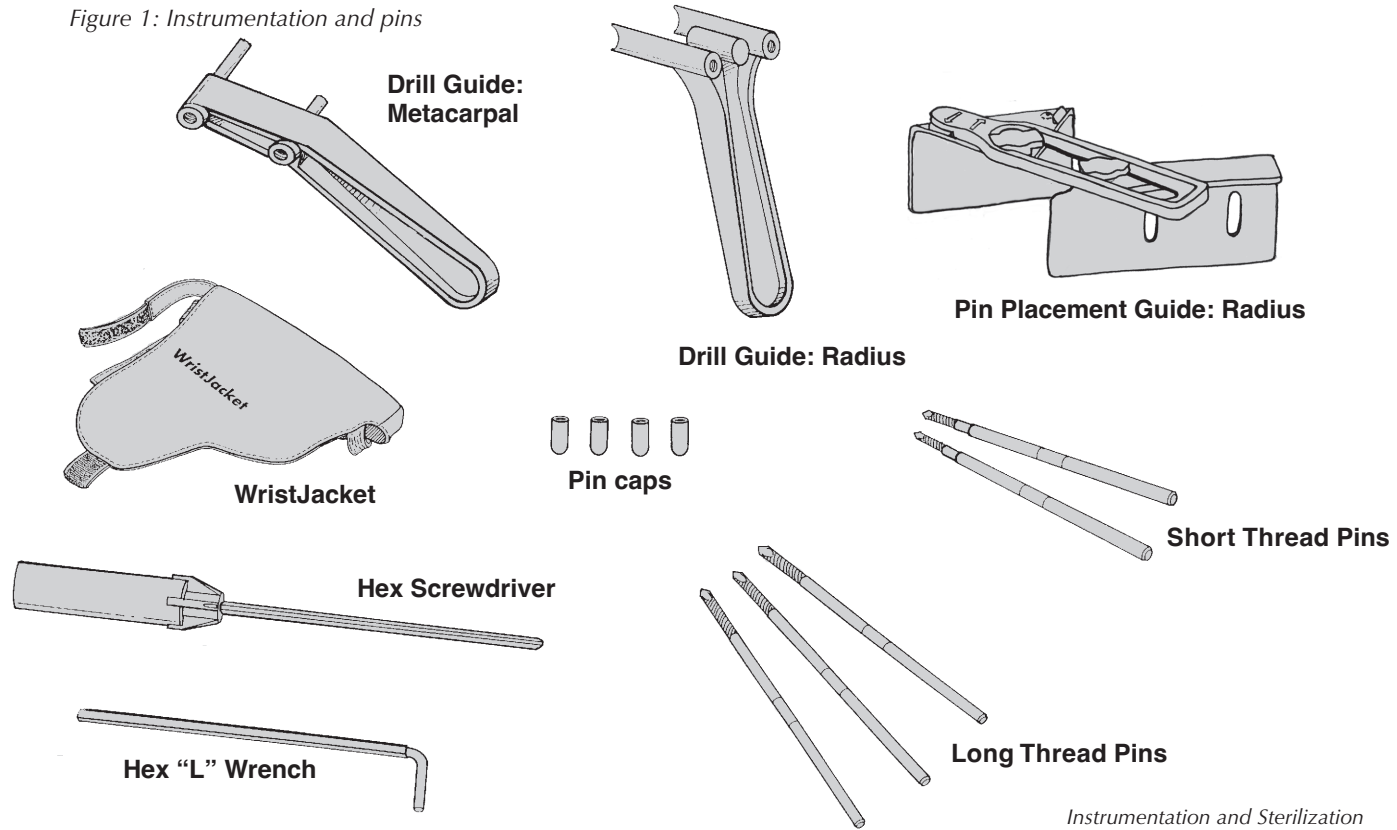
In addition, the following non-sterile item is provided to cover the WristJack after installation:

- Wristjacket

**CAUTION: Tray contents are STERILE unless packaging has been opened or damaged.**

**CAUTION: Do not reuse the WristJack fixator, instrumentation or fixation pins. They are not designed to safely withstand multiple patient use.**

Figure 1: Instrumentation and pins



## INDICATIONS FOR USE

---

This WristJack is indicated for treatment of distal radius fractures that require external skeletal fixation as defined by the judgment of the treating surgeon as well as the orthopaedic literature that he/she chooses to respect.

**If persistent displacement of key bone fragments cannot be reduced with external fixation alone, consideration should be given to combining external fixation with percutaneous pinning or open reduction and internal fixation of the key displaced fragments. Anatomical voids from crushed metaphyseal bone that are evident following length restoration may require bone grafting.**

Highly unstable fractures may require a long arm splint or cast. Injuries that involve the distal radio-ulnar joint may benefit from additional support that holds the forearm in some degree of supination. Supination will typically improve stability and reduction of this joint.

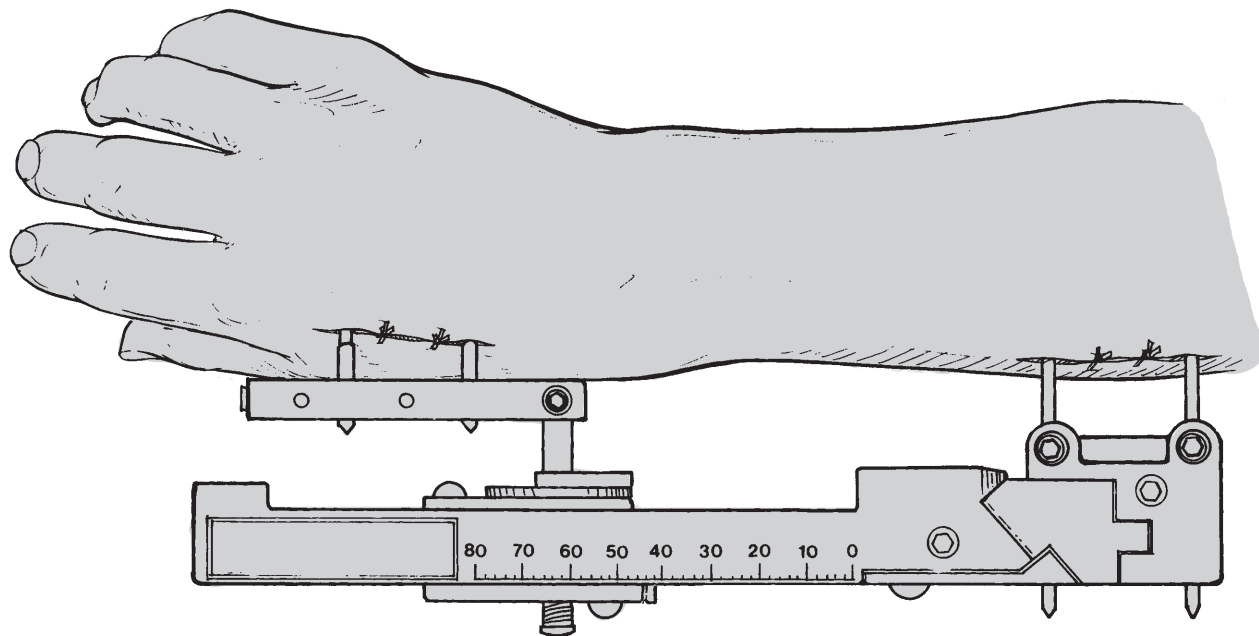
Preoperative radiographs should include multiple projections of the involved wrist and hand and the ipsilateral elbow. This is important as the same forces that fracture the distal radius not uncommonly injure the elbow, especially

its radial head. In addition, biplanar radiographs of the uninjured wrist are helpful in assessing the adequacy of skeletal length restoration, angular alignment of the distal radial articular surface as well as relative length of the radius and ulna.

The surgical procedure is summarized below:

- Under appropriate anesthesia, horizontal finger trap traction is used with gentle manipulation of the hand on the forearm to obtain gross alignment of the fracture.
- Skeletal pins are placed in the metacarpals and radius of the hand and forearm. The WristJack is installed on the pins. Fracture reduction is accomplished through selective adjustment of the gear mechanisms. Fracture alignment is determined with gentle palpation and visualization using radiographs or fluoroscopy.
- Following installation and adjustment, the wrist may be positioned in a neutral to extended position without compromising fracture reduction.

Figure 2: The WristJack

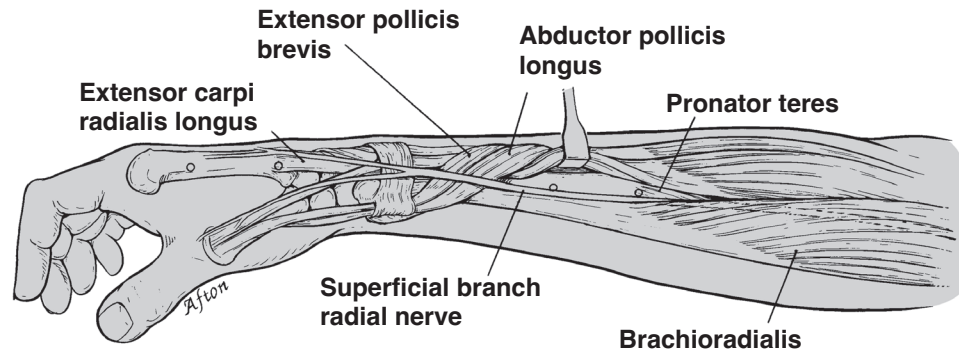


## SURGICAL ANATOMY

### Surgical Anatomy

Two pairs of pins are used to secure the WristJack fixator to the skeleton. The locations of these pins are shown below:

- The distal set of pins is inserted into the radial side of the index metacarpal. Note that the proximal of these is inserted through the tendon of insertion of the extensor carpi radialis longus.
- The proximal pin set is inserted into the “bare spot” that is palpable on the mid-radial aspect of the radius palmar to the wrist extensor muscles and dorsal to the brachioradialis. Note the tendon of insertion of the pronator teres and the course of the radial nerve.
- The drill guides provided with the WristJack are designed specifically to be used through an open incision that exposes the bone.

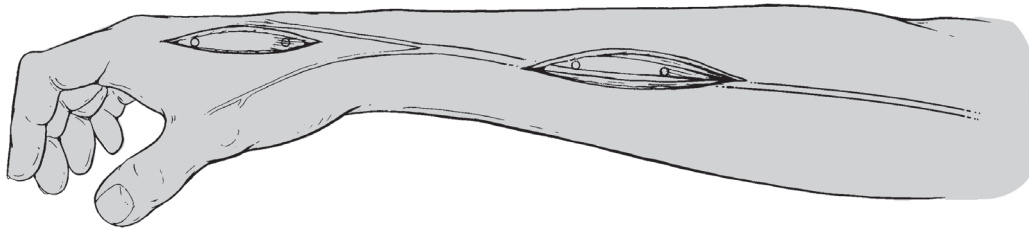


## SKIN INCISIONS

### Skin Incisions

Open incisions are used when inserting the skeletal pins:

- This allows accurate identification and protection of the radial nerve and its branches.
- Full visualization prevents unintentional pinning of the muscle-tendon units to the skeleton.
- Pin placement accuracy is improved. Correct pin placement is important to take full advantage of the device adjustments.



## METACARPAL PIN INSERTION

*Insertion of the first metacarpal pin into the index and long finger metacarpal bases*

---

- ▲ NOTE: Closed reduction of the fracture and use of traction during pin insertion are important for proper pin placement.

### PREPARATION

Under appropriate anesthesia, use gentle manipulation combined with finger trap traction (preferably horizontal over the surface of a hand table) to obtain gross alignment of the fracture.

### PIN SELECTION

A long thread pin should be used in the base of the index and long finger metacarpals. For only the very smallest hands, substitute a short thread pin to minimize the risk of metacarpal fracture.

### SKIN INCISION

A longitudinal incision is made over the mid-radial aspect of the index metacarpal exposing its proximal two-thirds (see inset). Identify the tendon of insertion of the extensor carpi radialis longus and protect the branches of the radial nerve.

### DRILL GUIDE

Position the metacarpal drill guide as depicted, pressing its sharpened tubular tip on the tendon of insertion of the extensor carpi radialis longus overlying the metaphyseal base of the bone. An insertion immediately proximal to the fibers of the first dorsal interosseous muscle avoids inadvertent insertion into the carpometacarpal joint.

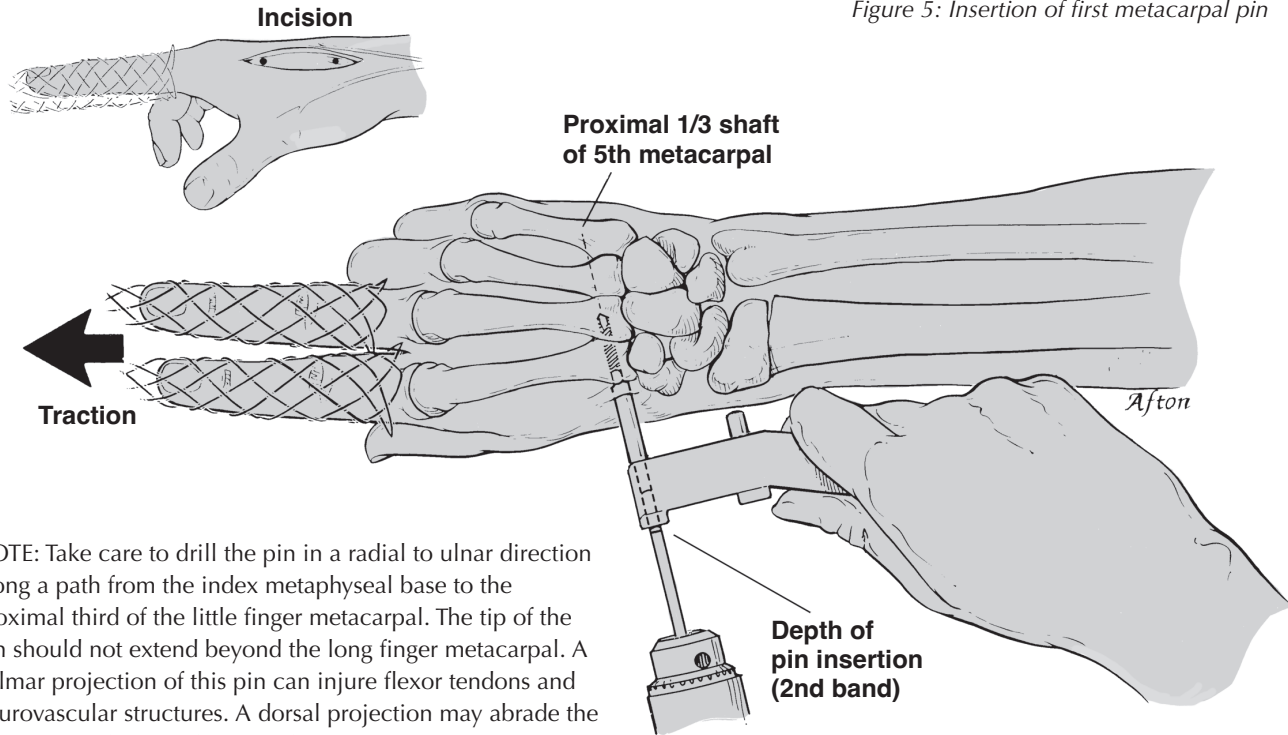
### PIN INSERTION AND DEPTH MEASUREMENT

While aiming at the proximal third of the little finger metacarpal, drill the first pin through the tendon and index metacarpal into the base of the long finger metacarpal. Insertion extends from radial to ulnar in a plane created by the finger metacarpals.

Depth can be estimated using the pair of bands on each pin. On an average-sized hand, the band nearest the pin tip will be hidden inside the drill guide and the second band will be visible near its surface. Check pin placement with C-arm fluoroscopy as needed.



Figure 5: Insertion of first metacarpal pin



- ▲ **NOTE:** Take care to drill the pin in a radial to ulnar direction along a path from the index metaphyseal base to the proximal third of the little finger metacarpal. The tip of the pin should not extend beyond the long finger metacarpal. A palmar projection of this pin can injure flexor tendons and neurovascular structures. A dorsal projection may abrade the extensor tendons on the pin's sharp tip.

## METACARPAL PIN INSERTION

*Insertion of the second pin into the index metacarpal shaft*

---

### PIN SELECTION

Use a short thread pin.

### DRILL GUIDE

Slide the body of the metacarpal drill guide over the first metacarpal pin as depicted.

### PIN INSERTION AND DEPTH MEASUREMENT

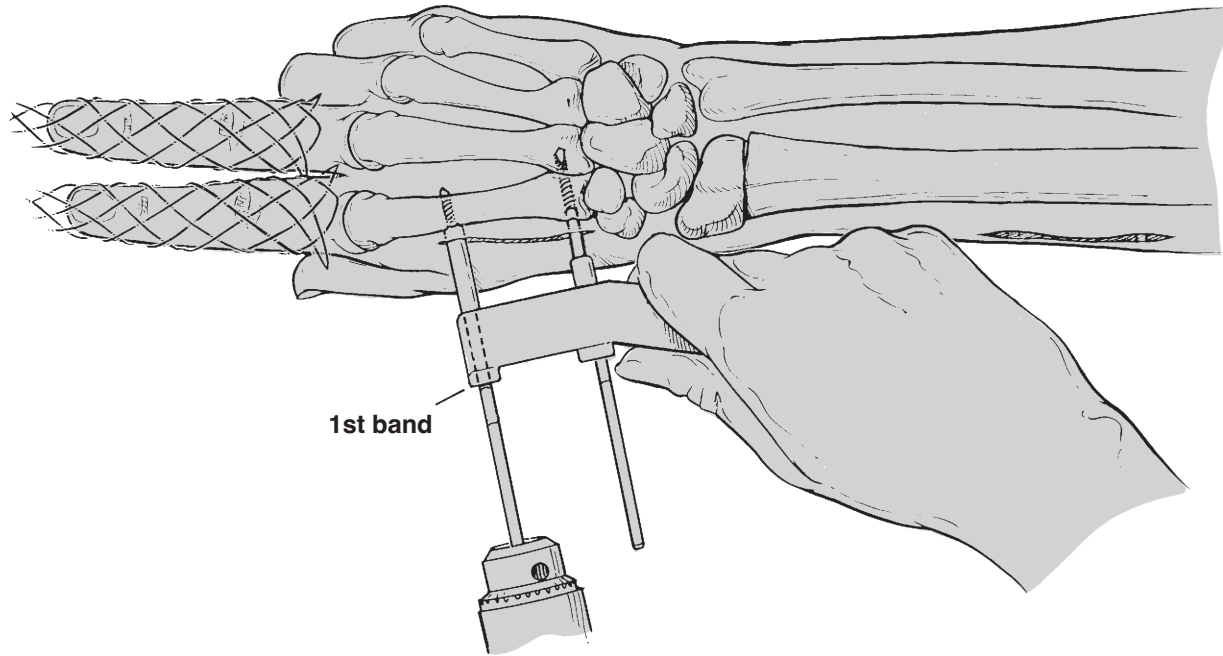
Firmly center the sharpened tip of the tube on the bone, then drill the pin through both cortices of the index metacarpal as illustrated.

The proper depth typically places the first band on the pin flush with the surface of the drill guide.

**CAUTION:** As depicted, use only the distal, serrated tube of metacarpal drill guide for pin insertion. The shorter, blunt tube is designed for positioning only. Drilling through the short tube may result in poor pin alignment or serious pin damage.

- ▲ **NOTE:** The pin should penetrate the center of the bone between the dorsal and palmar cortices. The tip of the pin should stop just beyond the shaft to avoid injury to the interosseous muscles. Check pin placement with C-arm fluoroscopy as needed.

*Figure 6: Insertion of the second metacarpal pin*



## **RADIAL SHAFT PIN INSERTION**

*The Pin Placement Guide helps identify the proximal-distal position of pins along the radial shaft*

---

### **RIGHT OR LEFT WRIST ADJUSTMENT**

For a right wrist, adjust the pin placement guide as depicted in Figure 7. For left wrist application, rotate the pivot arm to the opposite detent and flip the pen slot plate so the "Left" side will be visible when used.

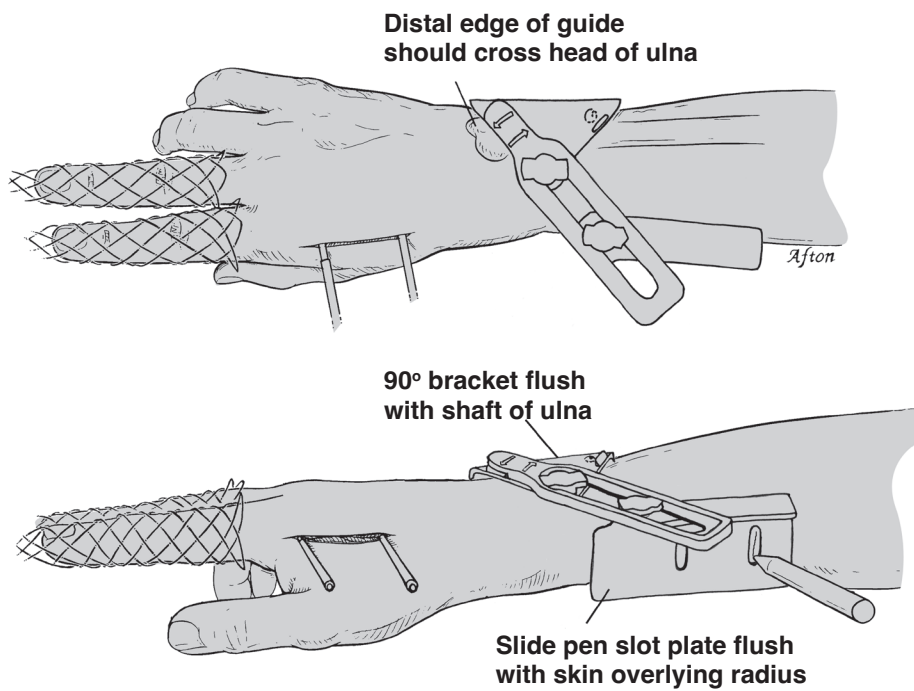
### **GUIDE POSITION**

As depicted in Figure 7, position the pin placement guide with its distal edge crossing over the head of the ulna. On the opposite side of the forearm, slide the pen slot plate flush against the overlying skin of the radius.

### **INCISION LOCATION**

Scribe two vertical lines through the slots with a skin marking pen.

Figure 7: Placement of radial shaft pins



## RADIAL SHAFT PIN INSERTION

*Making the incision for the radial shaft pins*

---

### SKIN INCISION

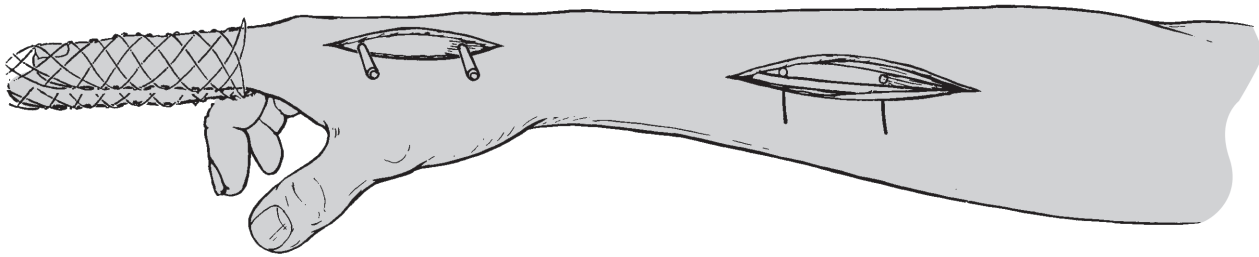
Locate the radius by palpation. Make a longitudinal skin incision extending approximately 1 cm proximal and distal to the lines as depicted. Note that the incision typically crosses the dorsal ends of the scribe lines.

### EXPOSURE OF THE RADIAL SHAFT “BARE SPOT”

The “bare spot” is exposed by incising the deep fascia then retracting the wrist extensors dorsally and the brachioradialis palmarly.

- ▲ NOTE: Care should be taken to identify and retract the radial nerve, which emerges from proximal and deep to distal and superficial as it crosses the dorsal edge of the brachioradialis.

*Figure 8: Incision for radial shaft pins*



## RADIAL SHAFT PIN INSERTION

### *Insertion of the first radial shaft pin*

---

- ▲ NOTE: Finger trap traction combined with gentle manual fracture reduction helps assure rotational alignment of the fracture. This alignment is necessary for optimal pin placement.

#### PIN SELECTION

Use a long thread pin.

#### DRILL GUIDE

Use closed manipulative reduction and longitudinal finger trap traction to obtain gross rotational alignment of the fracture. Retract the radial nerve and expose the radius shaft in the interval between the wrist extensor and brachioradialis muscles. Align the drill guide with the vertical scribe lines on the skin. The proximal pin should be positioned through or just distal to the tendon of insertion of the pronator teres muscle.

- ▲ NOTE: To allow full use of fracture reduction adjustments, it is important to align the radius pins in a plane parallel to the metacarpal pins. This is best accomplished by inserting the radius pins after

obtaining gross rotational alignment of the fracture. Although the pin's line of insertion can be "visualized" by palpating and then aiming at the shaft of the ulna (see cross-section view), scissoring of the forearm bones secondary to instability at the fracture site may compromise the ability of this technique to ensure optimal pin alignment.

#### PIN INSERTION AND DEPTH MEASUREMENT

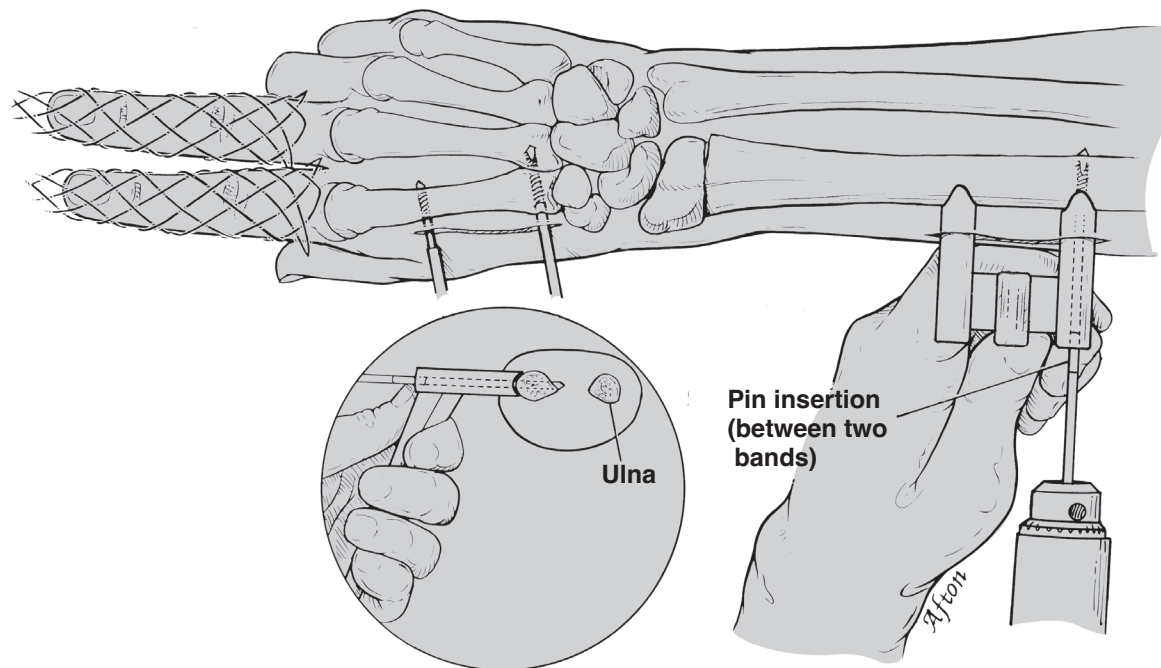
With the contoured feet of the drill guide firmly embracing the convex surface of the bone, drill the pin through both cortices of the radius. The final position of the pin should extend just beyond the deep cortex of the radius. This depth can be determined by a change in the pitch of the drill motor as the pin passes through the cortices of the radius.

The proper depth can be estimated when a point between the two depth bands is at the surface of the drill guide.

- ▲ NOTE: Keep both drill guide feet securely on the bone during insertion to ensure that the pins are aligned perpendicular to the shaft of the radius.



Figure 9: Insertion of the first pin in radial shaft



## RADIAL SHAFT PIN INSERTION

*Insertion of the second radial shaft pin*

---

### PIN SELECTION

Use a long thread pin.

### DRILL GUIDE

With the drill guide positioned by the first pin, ensure that the drill guide feet still firmly embrace the shaft of the radius.

### PIN INSERTION AND DEPTH MEASUREMENT

Drill the second pin through both cortices of the radius. The final position of the pin should also extend just beyond the deep cortex of the radius. As previously stated, this depth can be determined by a change in the pitch of the drill motor as the pin passes through the cortices of the radius.

▲ NOTE: This depth can be estimated when a point between the two depth bands is at the surface of the drill guide.

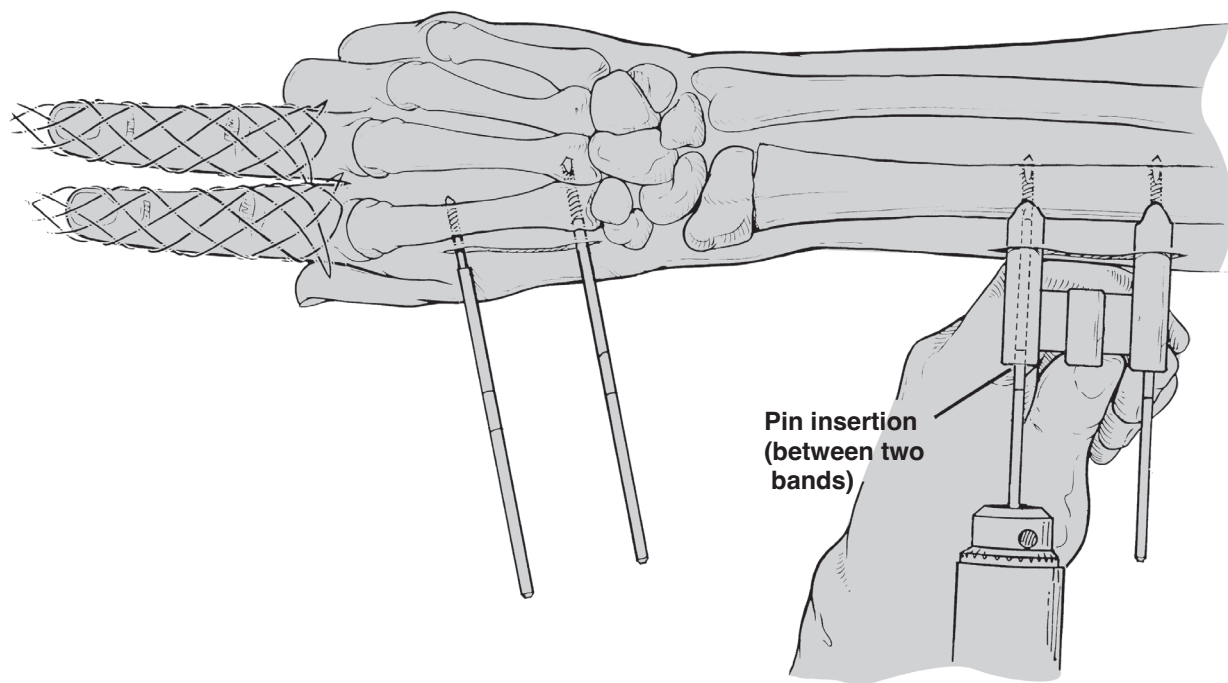
### VERIFY PIN POSITION

Use radiographs or fluoroscopy to confirm proper positioning and penetration depth of all four skeletal pins. Make necessary pin adjustments before proceeding.

### WOUND CLOSURE

Close both wounds loosely with interrupted sutures. Ensure that there is no pin pressure on the skin.

Figure 10: Insertion of the second pin in radial shaft

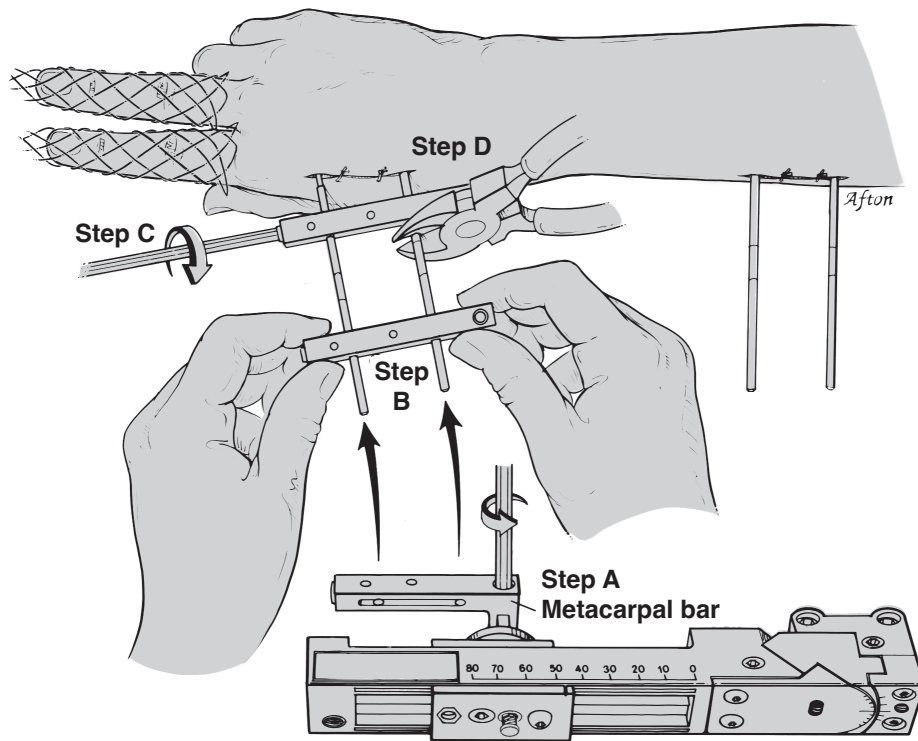


## INSTALLING THE METACARPAL BAR

---

- A. Remove the metacarpal bar from the WristJack by loosening the set screw marked "LOCK" at the proximal end of the bar and sliding the bar off the main unit.
- B. Loosen the distal "LOCK" screw and slide the metacarpal bar onto the metacarpal pins. Note the orientation of the side marked "DORSAL." Position the bar from 1/2 - 1 cm (one finger width) away from the thumb carpometacarpal joint thereby avoiding pressure on the overlying skin.
- C. Tighten the distal metacarpal pin "LOCK" screw to secure the bar to the pins. Verify that proper skin clearance still exists. Adjust if necessary.
- D. Cut off the pins flush with the metacarpal bar.

Figure 11: Installation of metacarpal bar



## INSTALLING THE WristJack ON THE PINS

---

A. Slide the WristJack onto the proximal pins, positioning the device 2-3 cm from the skin. **DO NOT CUT OFF THE EXCESS PIN LENGTH AT THIS TIME.**

B. Position the hand with the metacarpal bar parallel to the WristJack. Insert the screwdriver through the red adjustment hole in the distal end of the beam and engage the hex socket in the trolley. Adjust the trolley position until the bar aligns with the square shaft.

- Counterclockwise = Lengthen
- Clockwise = Shorten

C. Slide the metacarpal bar onto the square shaft until it stops against the shoulder.

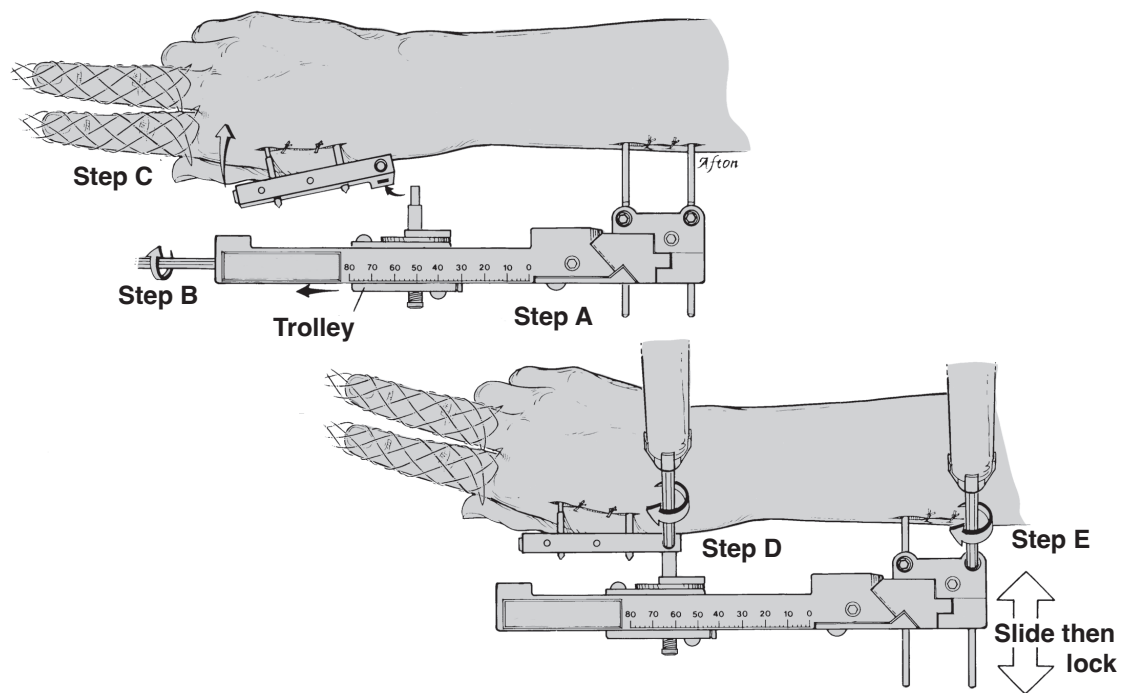
D. Tighten the proximal “LOCK” screw to secure the metacarpal bar to the WristJack.

E. If the hand is malaligned on the forearm in a radial or ulnar direction, slide the WristJack in or out on the radial shaft pins as needed. Tighten the “LOCK” screws with **LIGHT TORQUE.**

**CAUTION: Overtightening the radial shaft pin lock screws will not improve the stability of the unit and may cause thread damage or failure of the plastic component. Use only enough torque to prevent the set screws from loosening.**

▲ NOTE: Do not cut off the pin excess length at this time.

Figure 12: Installation of WristJack



## SELECTIVE FRACTURE REDUCTION

*Restoring length to the radius using the RED adjustment*

---

Remove finger traction.

Insert the hex screwdriver through the RED hole in the distal end of the beam and engage the gear in the trolley. Rotate the gear until the length of the radius is clinically restored. Length restoration occurs simultaneously with first note of finger MP joint extension. Use the centimeter scale printed on the beam to judge relative changes in length.

- Counterclockwise = Lengthen
- Clockwise = Shorten
- Each rotation = 1.6 mm (1/16")

Use C-arm fluoroscopy, if needed, to determine skeletal length restoration and carpal distraction. The first radiographic analysis of fracture reduction can typically follow length restoration and palmar translation (red and green adjustments).

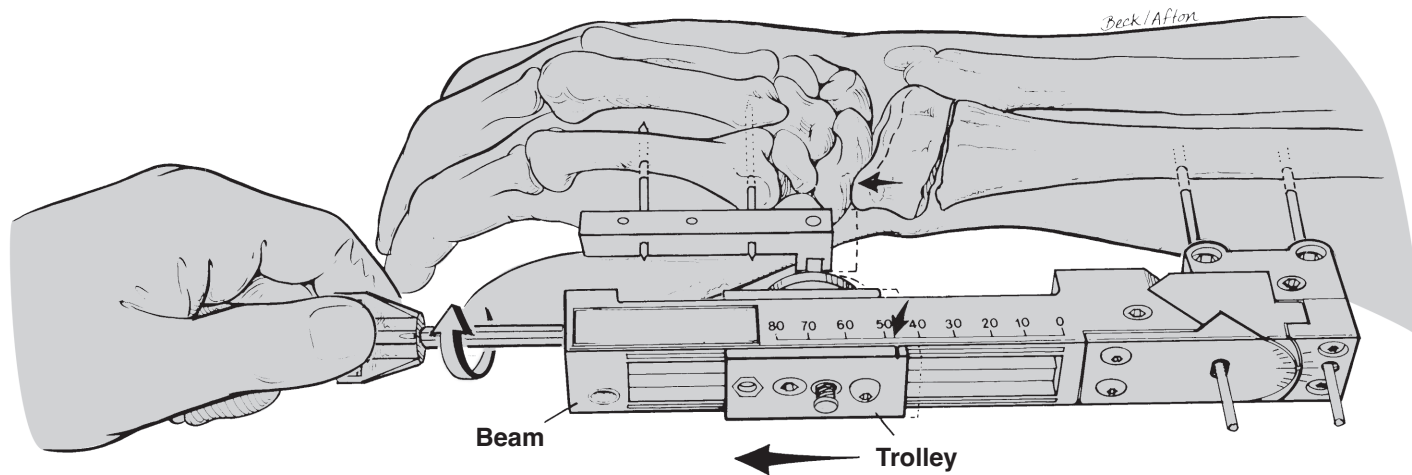
The degree of extensor tendon over pull can be estimated clinically by passively flexing the tip of the index finger to the palm. This test for extrinsic tightness indicates increased carpal height secondary to excess distraction of the carpus.

▲ NOTE: Care should be taken to avoid excessive traction. It may distract the fracture site and delay fracture healing. Excessive traction also transmits tension forces into the finger extensor tendons and can cause clawing of the fingers and a tendency to develop metacarpophalangeal (MP) joint extension contractures. (See page 39 in the Reference section for additional information on the perils of excessive traction.)

Follow up radiographs should be taken a few days to a week following application of the device to determine if the wrist is overdistracted. The traction forces used for fracture reduction can increase fracture site distraction a few days following external fixation. (A more detailed discussion of this topic is on page 36, Clinical Course and Fixator Removal: Overdistraction.)



Figure 13: Restoring length to the radius



## SELECTIVE FRACTURE REDUCTION

*Rotational alignment of the fracture site using the YELLOW adjustment*

---

Determine rotational alignment of the fracture through a physical comparison of passive supination and pronation with the uninjured forearm with the elbow flexed at 90°.

- ▲ NOTE: Typical installation of the WristJack does not require rotational adjustment. If forearm rotation is satisfactory, proceed to the dorsal/palmar adjustment.

To adjust rotational alignment, insert the hex screwdriver into the adjustment gear marked with a YELLOW ring. Rotate the gear until the forearm rotation is normal and/or symmetric with the uninjured side.

- Clockwise = Pronate fragment(s) about radius
- Counterclockwise = Supinate fragment(s) about radius

Palpate as necessary to determine alignment.

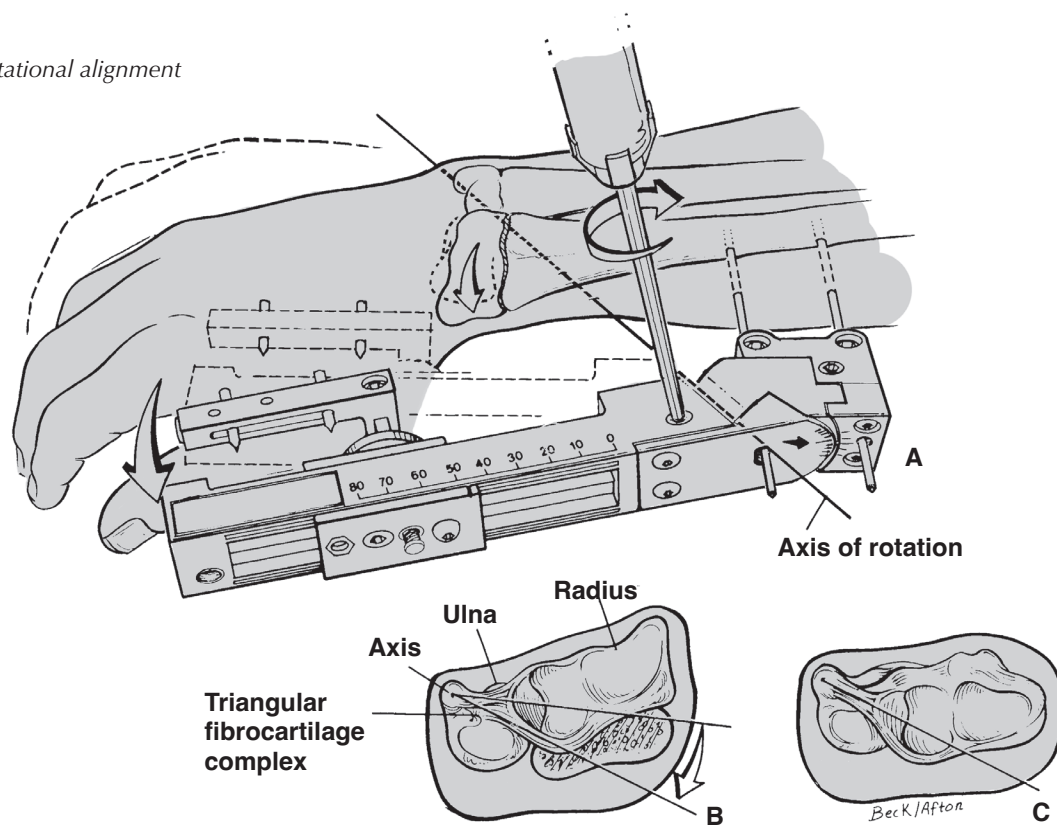
**CAUTION: Do not turn the adjustment past its stop. Doing so may damage the plastic gear and prevent further use of the adjustment.**

- ▲ NOTE Fig. A: Clockwise rotation of the YELLOW adjustment will pronate the distal fragment(s) on the radial shaft; counterclockwise rotation will supinate the fragment.

Fig. B & C: As the distal fragment is displaced dorsally, it is tethered and therefore rotated by the triangular fibrocartilage complex. This adjustment restores rotational alignment as it simultaneously improves appositional alignment (Fig. B to C); both of which are essential to optimal forearm rotation.

BIOMECHANICAL NOTE: In a Colles' type fracture, the distal fragment(s) of the radius rotates about the distal ulna (Figs. B & C). By projecting the axis of this adjustment to the rotational axis about which the deformity occurs, the distal fragment of the radius can be rotated selectively on the proximal shaft by single gear adjustment, thereby restoring rotational alignment.

Figure 14: Rotational alignment



## SELECTIVE FRACTURE REDUCTION

*Dorsal/palmar fracture alignment using the GREEN adjustment*

---

Insert the hex screwdriver into the adjustment gear marked with the GREEN ring. Rotate the gear to translate the distal fragment(s) as noted on the device.

- Clockwise = Translates fragment(s) palmarly
- Counterclockwise = Translates fragment(s) dorsally

**CAUTION: Do not turn the adjustment past its stop. Doing so may damage the plastic gear and prevent further use of the adjustment.**

Palpate and use fluoroscopy or radiographs as necessary to determine alignment.

The following figures demonstrate restoration of palmar tilt:

- A. Distracting forces combine with an intact dorsal periosteum to tilt and displace the distal fragment(s) dorsally.
- B. Clockwise rotation translates the hand palmarly, aligning the fragment(s) dorsally as the periosteum is reapposed.
- C. With an intact dorsal periosteal hinge “locked,” additional palmar translation rotates the distal fragment(s) and tilts its articular surface palmarly.

▲ NOTE: Excessive translation (using this GREEN adjustment) may tear a relatively intact periosteal hinge.

**Following restoration of palmar tilt, use the least palmar translation force necessary to maintain tilt.**

These illustrations depict a “simple” distal radius fracture with an intact dorsal periosteal hinge, which may not be present in some fractures requiring external skeletal fixation.

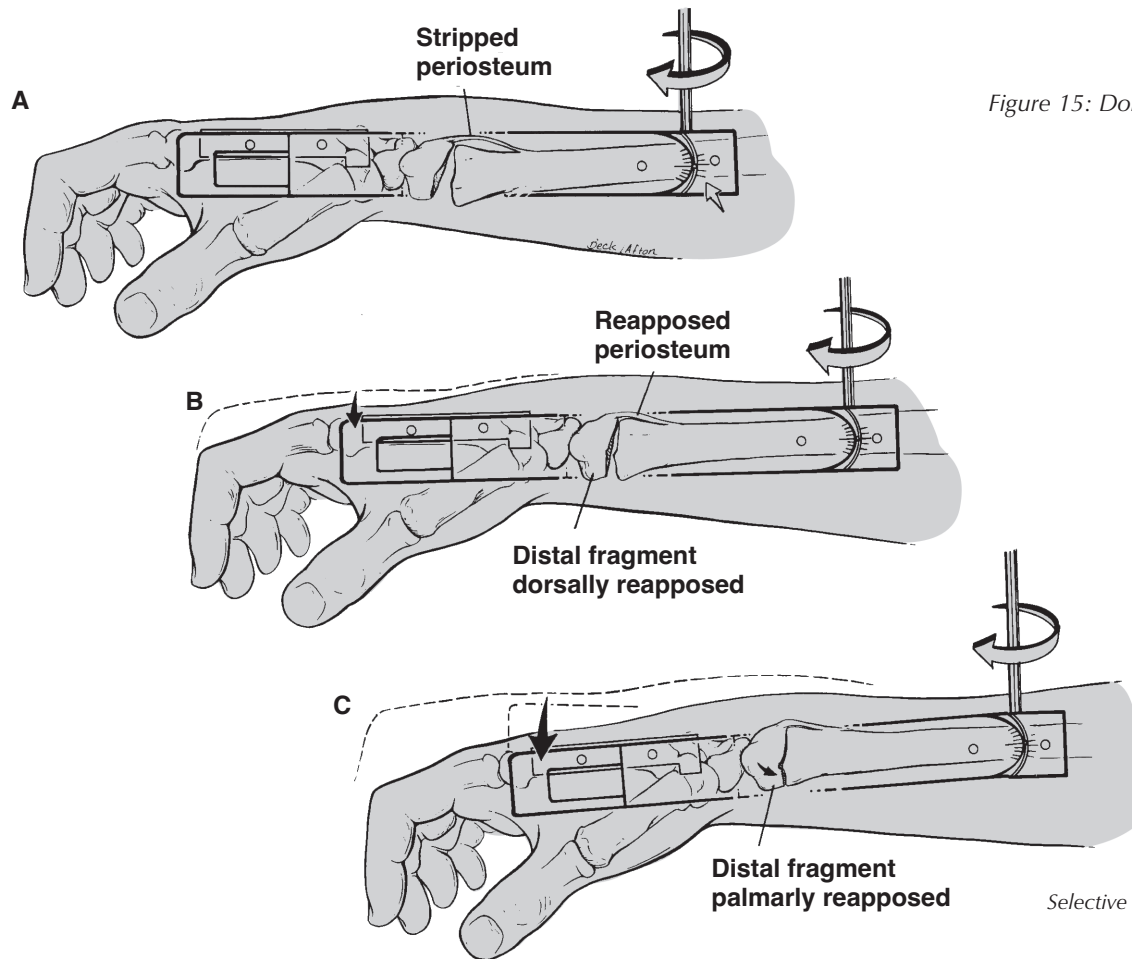


Figure 15: Dorsal/palmar alignment

## SELECTIVE FRACTURE REDUCTION

*Radial/ulnar fracture alignment using the BLUE adjustment*

---

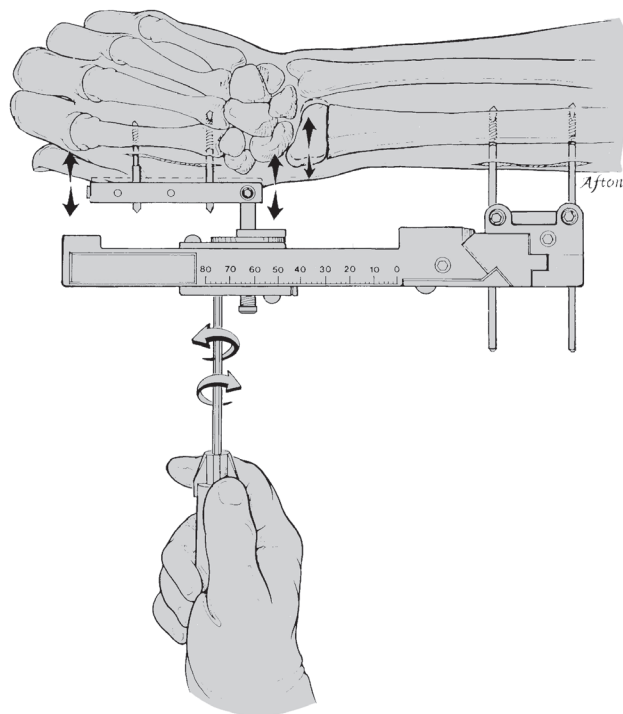
If the fracture is malaligned in the radial /ulnar plane, rotate the gear on the trolley marked with a BLUE ring.

- Clockwise = Translates fragment(s) ulnarly
- Counterclockwise = Translates fragment(s) radially

Palpate and use fluoroscopy or radiographs as necessary to determine alignment.

▲ NOTE: This adjustment is designed to “fine tune” appositional alignment, which is especially important in fractures of the radio-ulnar joint. If gross malalignment is present in a radial-ulnar direction, loosen the “LOCK” screws holding the radius pins. Slide the WristJACK in or out until alignment is improved, then re-tighten the “LOCK” screws. See Step E of illustration on page 23 for further information.

Figure 16: Radial/ulnar fragment



## WRIST POSITION FOR OPTIMAL HAND FUNCTION

*Selected using the VIOLET wrist lock screw*

---

- ▲ NOTE: Selecting the optimal wrist position is important to help avoid finger stiffness and carpal tunnel syndrome. See page 39 in the Reference section for further information on optimal wrist position.

The wrist lock screw is located on the trolley and is marked with a VIOLET ring.

Loosen the screw approximately 1/4 turn and adjust the wrist position by moving the hand in the flexion-extension plane.

Re-tighten the wrist lock screw.

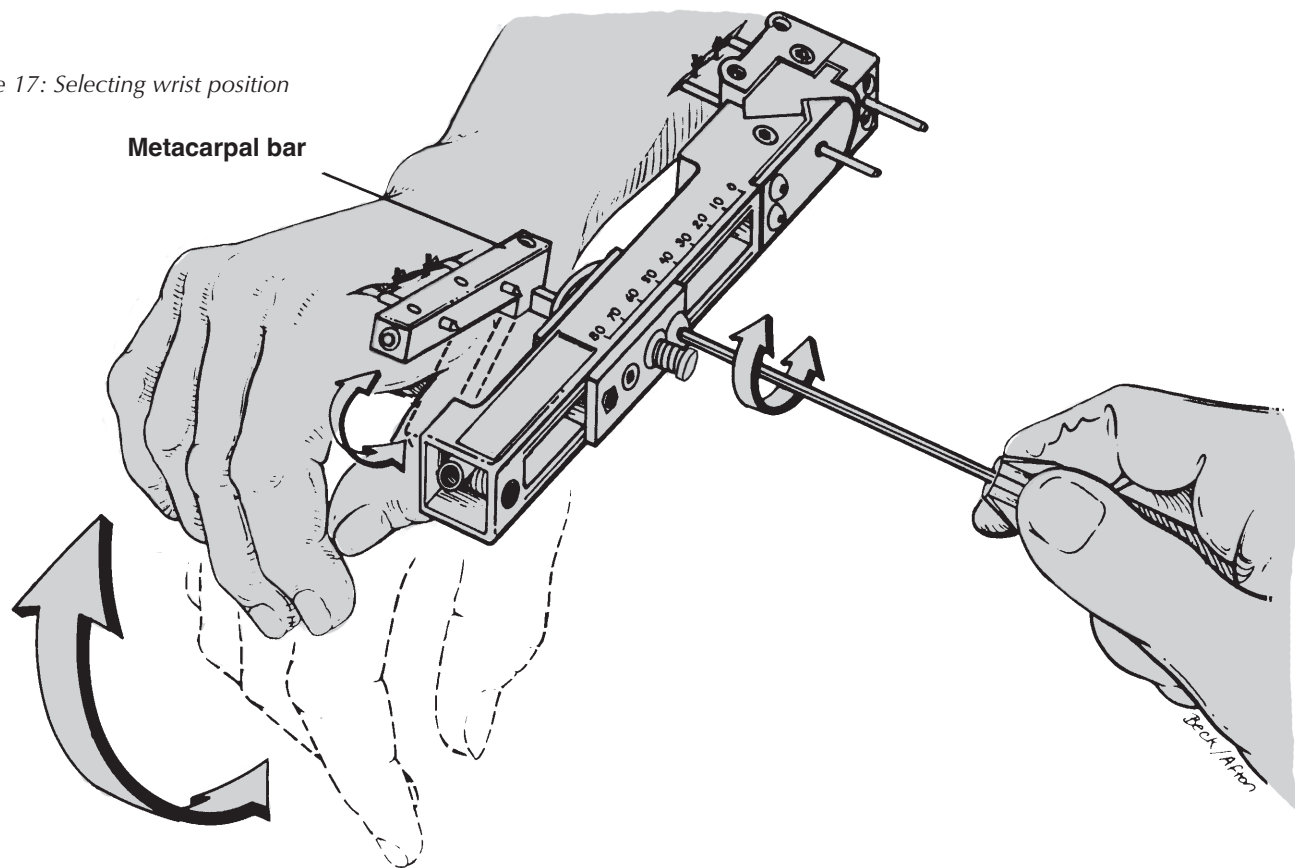
**CAUTION: Do not loosen the wrist lock screw to allow active or passive motion of the wrist during fracture healing. Doing so may cause the wrist lock mechanism to bind, preventing proper wrist position locking at a later time. Additionally, dynamic wrist motion may cause skeletal pin failure and/or compromised fracture healing.**

- ▲ NOTE: The axis of rotation for selecting wrist position projects through the center of the wrist joint. This permits wrist position adjustments relatively independent of fracture alignment adjustments.

In typical cases, a wrist neutral to extended position helps avoid finger stiffness and carpal tunnel syndrome. Careful radiographic and clinical assessment is necessary to identify those few cases which require a given wrist position to obtain reduction of the radius and/or radial-carpal joint.



Figure 17: Selecting wrist position



## FINAL CHECK AND ANALYSIS

---

X-ray the wrist in AP and lateral projections when clinical alignment, including forearm rotation, is satisfactory.

“Fine tune” the fracture reduction that is achieved with a given position of wrist flexion-extension using the WristJack adjustments.

Repeat final AP, lateral and both oblique radiographs if wrist position is changed. Although unlikely, it is possible for wrist position adjustments to affect fracture alignment.

Inspect the wounds and relieve any pressure on the skin adjacent to the pins by extending the incisions as necessary.

Secure all of the locking mechanisms on the device by tightening the five hex “LOCK” screws indicated by arrows.  
**Do not over-tighten the radial shaft pin “LOCK” screws.**  
**See caution on page 22.**

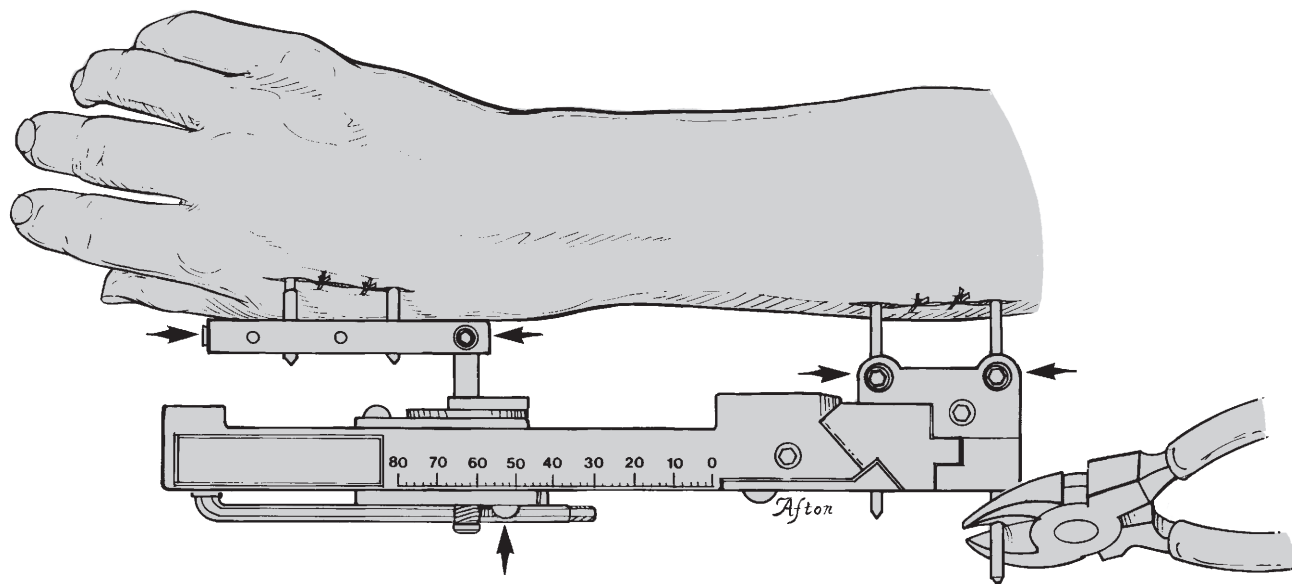
Cut the radial shaft pins close to the unit as depicted. Cover their sharp tips with pin caps.

Replace the hex “L” wrench in its receptacle on the WristJack main beam, holding it in place with tape for later use in the clinic.

▲ NOTE: If persistent displacement of key fragments cannot be reduced with external fixation alone, consideration should be given to combining external fixation with percutaneous pin manipulation or open reduction and internal fixation of these key displaced fragments. Anatomical voids from crushed metaphyseal bone that are evident following length restoration may benefit from bone grafting.

Highly unstable fractures may require additional support in the form of a long arm plaster splint or cast. Injuries that

Figure 18: Final Check



## CLINICAL COURSE AND FIXATOR REMOVAL

---

extend to involve the distal radio-ulnar joint require a long arm splint or cast to maintain a position of forearm rotation that improves the stability and reduction of this joint. In Colles' type fractures (with dorsal displacement of the distal fragment), maintenance of excessive palmar translation of the hand on the forearm aggravates dorsal subluxation of the head of the ulna with respect to the distal radius. The least palmar translation necessary to maintain palmar tilt works in synergy with forearm supination to help assure reduction of the distal radio-ulnar joint during fracture and soft tissue healing.

These and multiple other factors that affect the final result remain the responsibility of the treating surgeon as defined by his/her judgement and experience as well as the orthopaedic literature that he/she chooses to respect.

### **Overdistraction**

In the first week following external fixation of an acute fracture, repeat radiographs should be taken to determine if the wrist is overdistacted.

- ▲ NOTE: Overdistraction may lead to delayed fracture union and should be reduced or eliminated.

Compared to intra-operative radiographs, follow up images typically show a distracted carpus. This is demonstrated by increased cartilage space between the radius and scaphoid and the lunate and capitate. These widened spaces are evidence of the residual distraction forces at surgery that produced secondary lengthening of the soft tissues. This represents the stress-relaxation curve of the soft tissues.

Reduce an overdistacted wrist by turning the RED adjustment clockwise. Each rotation will move the trolley approximately 1.6 mm (1/16").

---

### **Fine tuning fracture alignment**

For several weeks following surgery, fracture alignment can be fine tuned with the WristJack adjustments. Care should be taken to reduce excessive longitudinal distraction and palmar translation. Clinical evidence of increasing finger stiffness should be treated by appropriate hand therapy, which may be enhanced by increased degrees of wrist extension and careful avoidance of overdistraction.

### **Fracture union**

Comminuted fractures typically require 8 - 10 weeks to develop union adequate to support fixator removal. This time interval is highly variable and its determination requires careful clinical assessment. In general, increasing degrees of bone and soft tissue injury are associated with progressive loss of bone apposition and with the potential for a delay or failure of fracture union. Optimal fracture reduction, the least distraction force necessary to maintain skeletal length and appropriate addition of bone graft work in synergy to help assure fracture union.

### **Fixator removal**

WristJack developer John M. Agee, M.D., typically removes the fixator in the office without sedation, narcotics or local anesthesia. A careful explanation of the procedure to the patient followed by a gentle removal of the fixator and pins produces minimal, if any, discomfort.

Remove the pin caps and/or tape covering the bone pin ends.

Loosen the three pin “LOCK” screws and the “LOCK” screw on the proximal end of the metacarpal bar. Use the supplied hex screwdriver or “L” wrench or any suitable 1/8” hex wrench. Gently work the fixator and/or the metacarpal bar off the pins.

Use a manual or variable speed power drill to rotate each pin slowly counterclockwise, taking care to minimize its displacement of the soft tissues as the tip exits the bone.

Administer appropriate wound care and therapy as needed.

## REFERENCE

---

### ***Multiplanar Ligamentotaxis™***

Ligamentotaxis is the principle of molding fracture fragments into alignment as a result of a force applied across a fracture by the surrounding intact soft tissues.

How ligamentotaxis applies to the WristJack: Forces applied to the skeleton and/or soft tissues are transmitted to other bones and soft tissues through intact soft tissues. If these forces are applied in a single direction or plane, as is the case with horizontal finger trap traction, the effect of ligamentotaxis applies to the same plane. The fragment moves longitudinally. This uniplanar ligamentotaxis does not always restore joint congruity or palmar tilt to the distal radius.

To improve fracture reduction and restore palmar tilt, ligamentotaxis can be applied in dorsal/palmar and radial/ulnar planes. For example, to correct a radially displaced fragment, a force is applied to the metacarpals in an ulnar direction. This force is transmitted through the intact soft

tissues, translating the fragments toward the ulna. The WristJack uses ligamentotaxis in multiple planes to achieve fracture reduction. The design of the unit allows “gear-driven” ligamentotaxis in one plane to be relatively independent of the other planes (*Multiplanar Ligamentotaxis*).

*Multiplanar Ligamentotaxis* extends the principle of uniplanar ligamentotaxis to include the translation of the hand in dorsal/palmar and radial/ulnar planes to effect appositional and tilting alignment of the distal fragment(s) of a fractured radius.

This creates a new standard for devices that not only provide external skeletal fixation but also selective reduction of the fracture.

---

**Optimal wrist position:**

The tension on the finger extensor tendons is relatively relaxed with the wrist in extension. This reduces the tendency of the finger metacarpophalangeal (MP) joints to stiffen in extension.

Wrist flexion has the opposite affect, resulting in relatively extended finger MP joints that can lead to extension contractures. In addition, wrist flexion predisposes to median nerve compression in the carpal tunnel.

For these reasons, a neutral to moderately extended position of the wrist is preferable and typically does not compromise fracture reduction. Wrist extension up to 20° is associated with the lowest carpal tunnel pressures and is therefore optimal for patients with signs or symptoms of median nerve compression.

**Perils of excessive traction**

External fixation typically restores skeletal length by maintaining traction forces during fracture healing. Excessive traction produces an increased incidence of complications:

- Delayed or non-union of the fracture
- Extrinsic extensor plus hand syndrome
- Reflex sympathetic dystrophy

Although an initial “overdistraction” of the fracture may be useful in fracture fragment alignment, maintenance of excessive traction often proves detrimental. A portion of this distraction force is transmitted into the finger extension tendons resulting in a clinically recognizable “clawing” of the fingers. This “intrinsic minus position” of the hand is actually an “extrinsic extensor plus” position of the finger MP joints. The degree of this deforming force can be estimated by passively flexing the finger tips to the distal

## REFERENCE

---

palmar crease, with the index finger being the most sensitive indicator of the biomechanical imbalance. Although some degree of distraction must be accepted for the external fixator to maintain skeletal length, the detrimental effect of that tension on the functional position of the hand can be minimized by a neutral or wrist extended position.

The use of advanced degrees of wrist extension (greater than 20°) may improve hand tendon mechanics at the expense of increased carpal tunnel pressures on the median nerve.

In summary, the least distraction force necessary to maintain skeletal length works in synergy with wrist extension to relax the finger extensor tendons and thereby help avoid hand stiffness.



## IMPORTANT MEDICAL INFORMATION

### WristJack Fracture Reduction System

---

#### INDICATIONS, CONTRAINDICATIONS & POSSIBLE ADVERSE EFFECTS

##### Indications

The WristJack is indicated for treatment of distal radius fractures that require external skeletal fixation as defined by the judgment of the treating surgeon as well as the orthopaedic literature that he/she chooses to respect.

##### Contraindications

Patients in whom cooperation or mental competence is lacking thereby reducing patient compliance; or those with alcohol or substance abuse problems that may lead to poor patient compliance.

##### Possible Adverse Effects

- Damage to nerves or vessels caused by insertion or presence of the skeletal pins.
- Damage to ligaments, tendons or other soft tissues caused by improper use of the device.
- Tissue necrosis during pin insertion.
- Superficial or deep pin track infection.
- Foreign body reaction to the pins, which are made of implant grade stainless steel containing nickel and other ingredients.
- Loosening or breakage of skeletal pins.
- Necessity for reoperation to replace a skeletal pin or the entire device.
- Pressure necrosis at the pin-tissue junction.

- 
- Skin pressure problems caused by external fixator components.
  - Excessive operative bleeding.
  - Septic arthritis and osteomyelitis.
  - Persistent drainage after pin removal; chronic pin-site osteomyelitis.
  - Persistent and/or residual deformity of the distal radius and/or radio-ulnar joint.
  - The intrinsic risks associated with anesthesia.
  - Inadvertent injury to the patient or operating room personnel caused by pin cutting during surgery.

---

## **WARNINGS AND PRECAUTIONS**

This device is intended for single use only and should be used in conjunction with recommended procedures and techniques.

### **Preoperative**

- Proper understanding of the device and surgeon's technique are essential. Physicians are strongly encouraged to study the Surgeon's Manual, which contains specific instructions and application notes regarding proper use of the device.
- Patient selection should be in accordance with the listed indications and contraindications.
- Patient should be informed of rationale, use and potential complications of the WristJack System.

- Patients with bilateral wrist fractures requiring bilateral WristJacks tend to put greater demands on their hands than a patient with a single WristJack. These patients should be educated to minimize forceful hand activities to reduce the risk of skeletal pin failure.

### **Intraoperative**

- Pin placement and orientation instructions contained in the Surgeon's Manual should be strictly followed. The described technique has been developed to minimize risk to precious soft tissue structures, ensure full use of the gear adjustments and avoid abnormal loading of the skeletal pins.
- Surgeon's Manual instructions, notes, cautions and reference material concerning proper use of device adjustments should be carefully reviewed and followed. Improper use of the device may lead to soft tissue damage, fracture malunion or nonunion.

---

### **Postoperative**

- Meticulous pin-site care is essential in minimizing pin track inflammation and/or infection. Deep (bone) infection may require pin removal and therefore premature device removal.
- Patient should be instructed to report any adverse or unanticipated effects immediately to the physician.
- The device should not be adjusted or loosened to accommodate active or passive motion of the wrist.
- Surgeon's Manual instructions, notes and cautions concerning use of fracture reduction adjustments should be reviewed and followed to minimize the incidence of delay and nonunion of the fracture, as well as complications such as carpal tunnel syndrome and hand stiffness.
- The skeletal pin and wrist position locking mechanisms should be checked routinely and tightened as necessary.

